Cranial Nerves 3, 4, and 6
Anatomy and Pathology

Asim F. Choudhri, M.D.
Associate Chair - Research, Chief of Neuroradiology, Department of Radiology
Professor of Radiology, Ophthalmology, and Neurosurgery
Le Bonheur Neuroscience Institute
University of Tennessee Health Science Center

Le Bonheur Children's Hospital
THE UNIVERSITY of TENNESSEE HEALTH SCIENCE CENTER

September 27, 2018 ASHNR 2018

Disclosures

- No conflicts to report

Goals

- Review the imaging anatomy of the ocular motor cranial nerves (III, IV, and VI)
  - From nucleus to extra-foraminal segments
- Review the imaging appearance of common (and uncommon) pathologic entities impacting cranial nerves
- Understand the clinical presentation of patients with ocular motor cranial neuropathies, and the associated terminology used by clinicians

Blitz segmentation

- Each nerve has multiple segments
  - Nucleus (1 or more)
  - Intraaxial segment
  - Cisternal segment
  - Dural cave
  - Inter-dural segment
  - Foraminal segment
  - Extra-foraminal segment

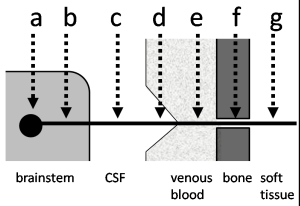

(Blitz et al., Neuroimaging clinics of North America 2013)

CISS/FIESTA

- A fluid sensitive technique that has high spatial resolution and is relatively resistant to CSF pulsation artifacts
- Great for evaluating cisternal segment of cranial nerves (where surrounded by CSF)
- Has T1 properties (T2*/T1), so contrast can be useful
  - interdural segments surrounded by venous blood
  - enhancing lesions

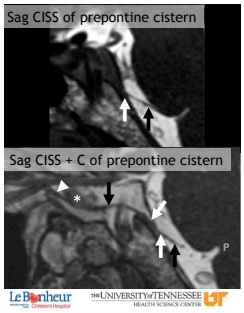

Common pathology

- Infectious/Inflammatory condition
  - Miller-Fisher
  - Bells palsy
- Impingement by an external structure
  - Vascular (e.g. aneurysm, direct vessel contact)
  - Mass
- Neoplasm
  - Nerve sheath tumor
  - Perineural spread of tumor
- Congenital dysplasia/absence

CN III - Oculomotor

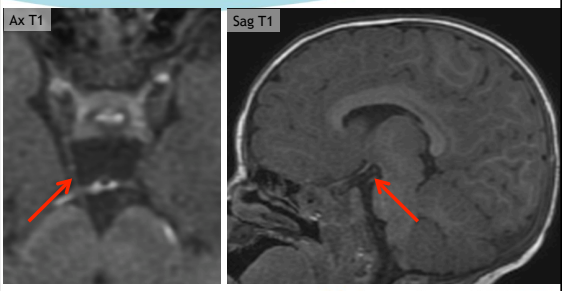

CN III - Oculomotor

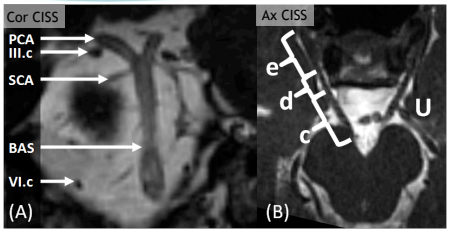

CN III - Oculomotor

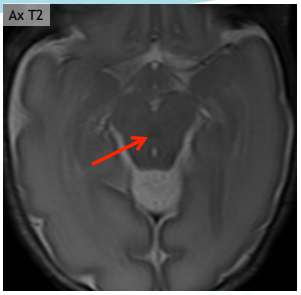

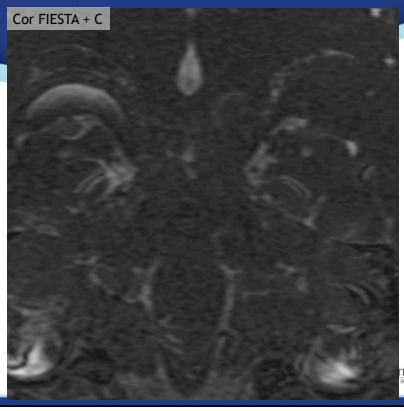

CN III - Oculomotor

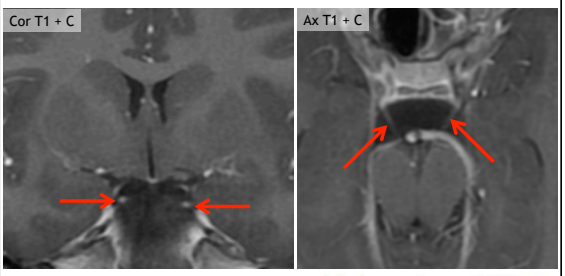

CN III - Oculomotor

Nerve	Foramen
Nucleus	Various in midbrain
Foramen	Superior orbital fissure
Fibers	Motor, parasympathetic
Motor ftn	All extra-ocular muscles except superior oblique and lateral rectus

CN IV - Trochlear

- Arises from the dorsal midbrain
- Decussates
- Very thin
- Innervates superior oblique

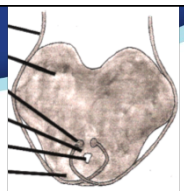

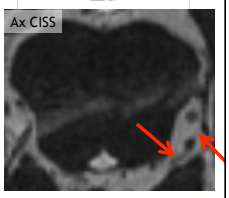

CN IV - Trochlear

- Nearly impossible to see the normal nerve on MR unless *very high resolution* sequences are used
  - 0.3 mm isotropic voxels needed to reliably see
  - 0.6 to 0.8 mm used for routine cranial nerve imaging

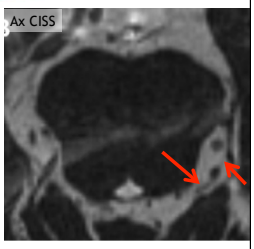

CN IV - Trochlear

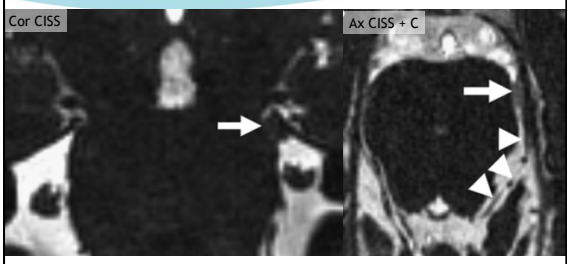

CN IV - Trochlear

Nerve	Foramen
Nucleus	Dorsal midbrain
Foramen	Superior orbital fissure
Fibers	Motor
Motor ftn	Superior oblique

CN VI - Abducens

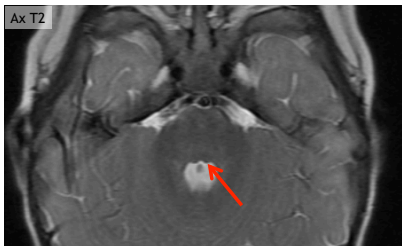

CN VI - Abducens

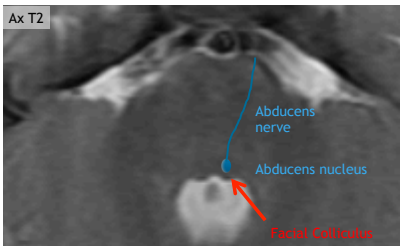

CN VI - Abducens

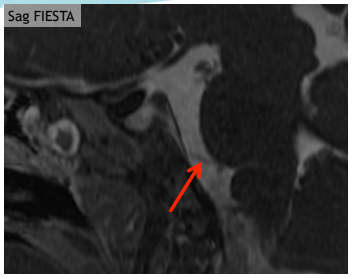

CN VI - Abducens

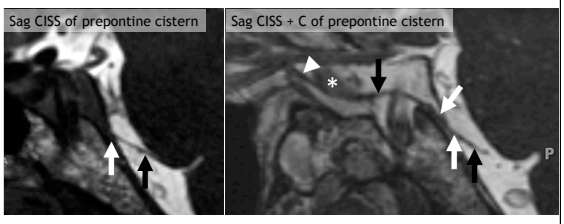

Cavernous sinus

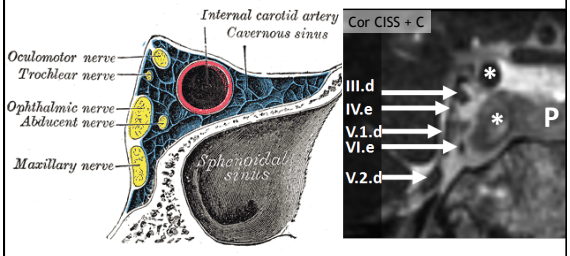

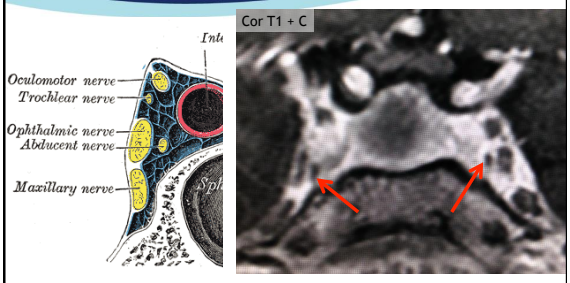

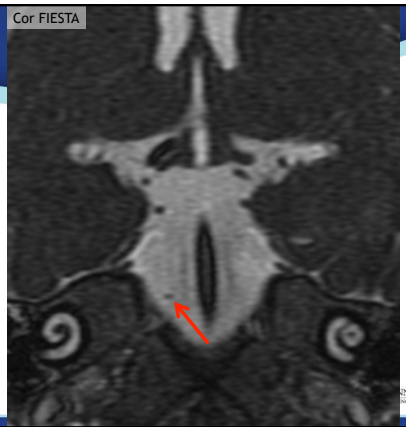

Bilateral absent CN VI

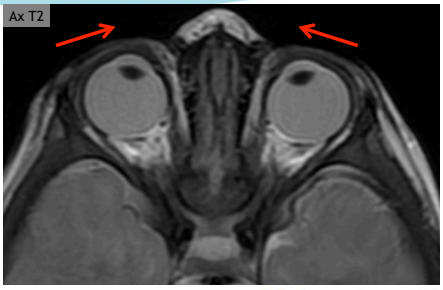

3mo, L CN VI palsy

3mo, L CN VI palsy

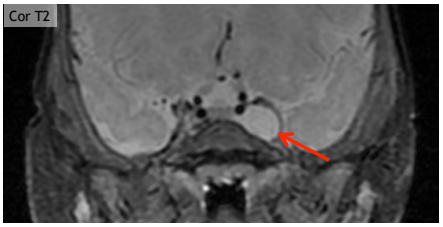

Trauma

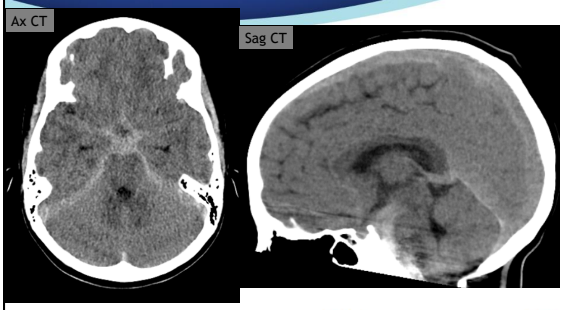

1 day later, new CN VI palsy

Post-traumatic CN VI palsy

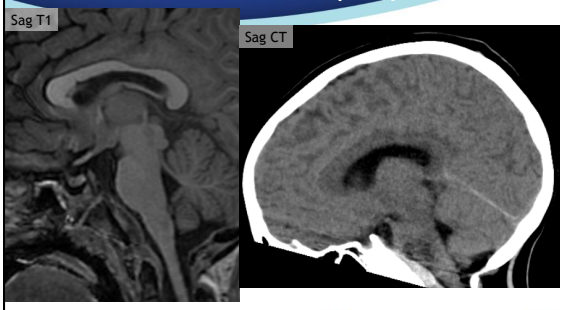

Post-traumatic CN VI palsy

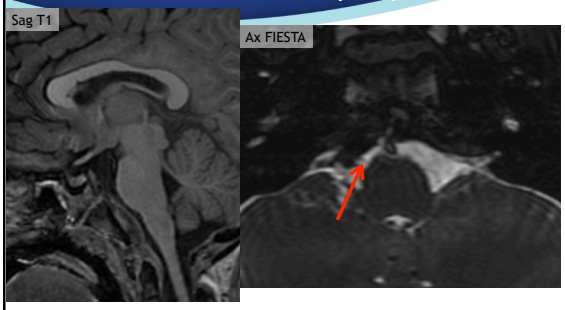

5 year old, left CN VI palsy

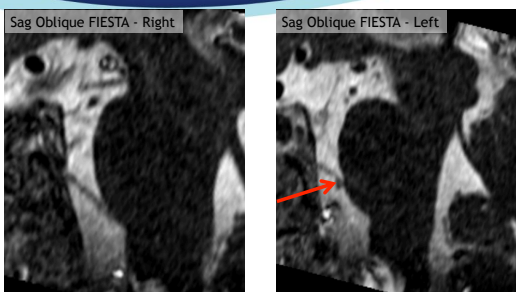

CN VI - Abducens

Nerve	Foramen
Nucleus	Abducens nucleus
Foramen	Superior orbital fissure
Fibers	Motor
Motor ftn	Lateral rectus

Function – CN III

Nerve	Foramen
Superior rectus	Elevate, ADduction, intorsion
Medial rectus	ADduction
Inferior rectus	Depress, ADduction, extorsion
Inferior oblique	Elevate, ABduction, extorsion
Parasympathetic	Pupil constriction, lacrimation

Function – CN IV

Nerve	Foramen
Superior oblique	Intorsion, Depression, ABduction

Function – CN VI

Nerve	Foramen
Lateral rectus	ABduction

Diplopia

- Simultaneous perception of two images
  - "Double vision"
- Images may be displaced horizontally, vertically, obliquely, or torsionally
  - Each of these may have characteristic associations
- May be present at all times, or only in certain circumstances
  - e.g. present with lateral gaze, but not at neutral

Diplopia

Horizontal

Vertical

Oblique

Torsion

Diplopia

Critical question: one eye vs both eyes?

- If diplopia persists when covering one eye, then it is likely related to a refractive abnormality
  - e.g. corneal scarring, dry eye, lens abnormality, floater, retinal detachment, etc.
  - Not typically a CT or MRI issue
  - If diplopia goes away when covering one eye, then it is likely related to eye misalignment
  - Imaging often warranted for new onset double vision in an adult

Diplopia

- If diplopia in neutral position when looking straight ahead, the eyes are likely misaligned
  - Often related to an abnormality in EOM innervation

Diplopia in children

- Must have mature binocular vision to have diplopia
- Diplopia not typically present in young kids
- In young children, the brain will typically ignore one image if it can not fuse the visual information
  - If not corrected, this results in amblyopia
  - Amblyopia is loss of vision in the setting of a normal eye (abnormal brain processing of the visual information)

Esotropia in children

- Idiopathic esotropia in children is treated by strabismus surgery
- This may involve shortening the tendon of the lateral rectus muscle to increase the relative strength of the muscle
- This may involve moving the insertion of the medial rectus more anteriorly to increase the relative strength of the muscle
- MRI may be performed to look for alternative causes

Esotropia in children

- Accommodative esotropia is when there is an asymmetry in refraction between the two eyes
  - Often presents at approximately 2.5 years of age
  - Raises concern for a brain tumor
- The brain can not fuse the images, so one eye drifts inward to help ignore the visual stimulus from that eye
- Typically corrected with glasses

Diplopia related to strabismus

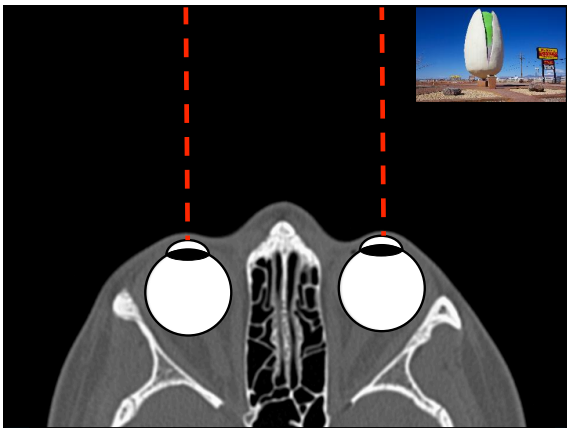

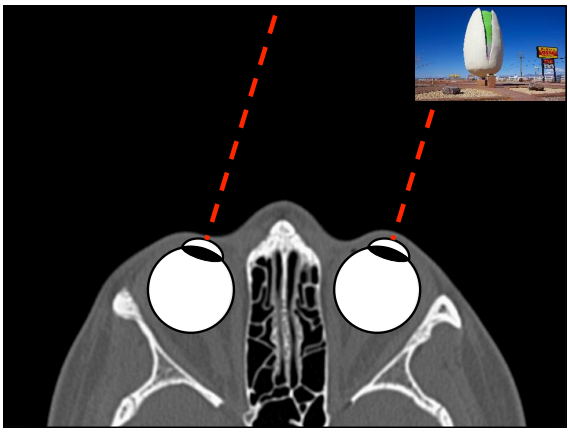

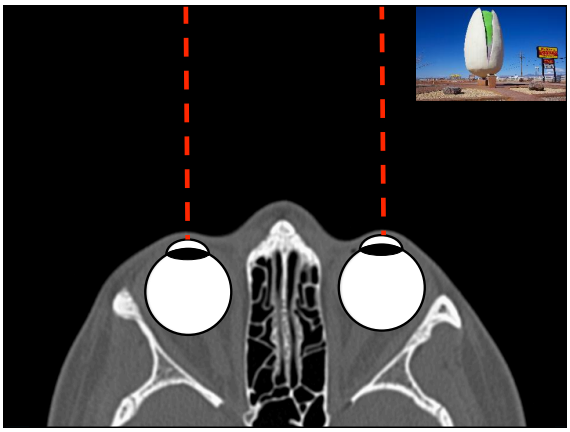

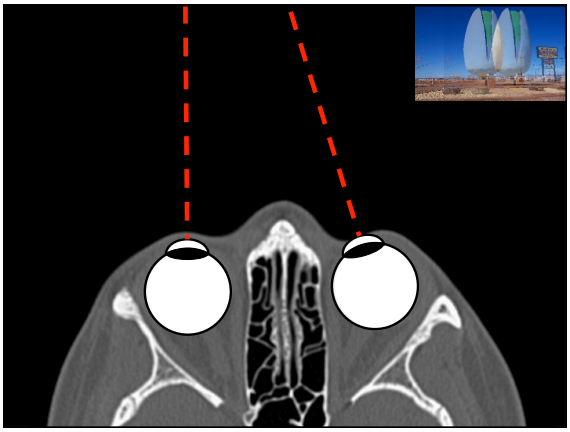

Linking diplopia to muscle function

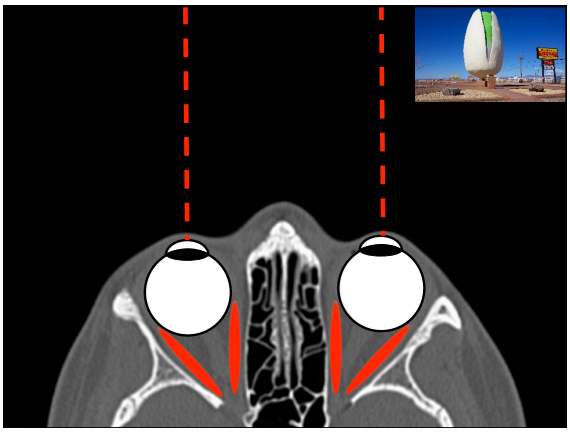

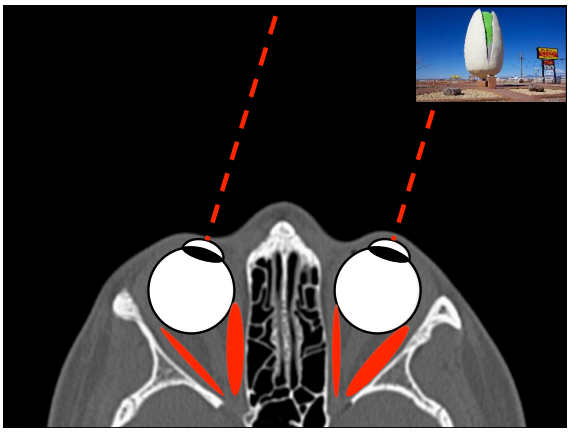

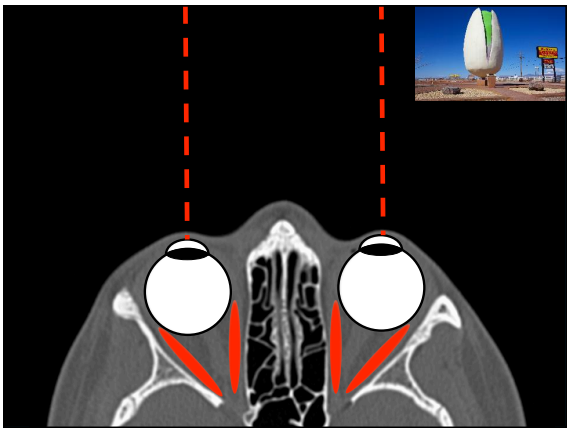

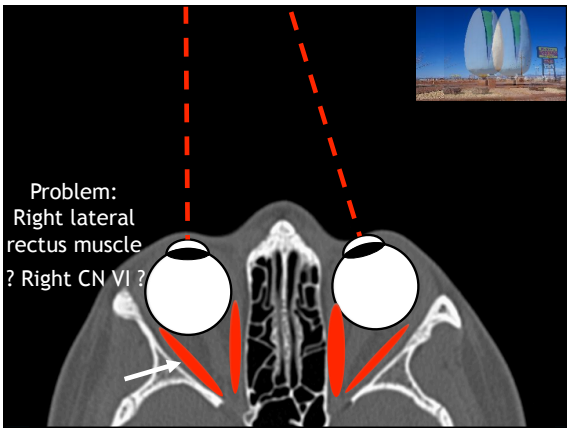

Case:
Diplopia with right gaze

- When looking left, the left lateral rectus and right medial rectus contract, no double vision
  - Left lateral rectus and right medial rectus intact
- When looking right, the right lateral rectus and left medial rectus contract
  - One of these is not working correctly
  - Likely right lateral rectus related to a right CN VI palsy

Case:
Diplopia with right gaze

- Lesion in the right ventral inferolateral aspect of the pons, along the margin of the pontomedullary sulcus, consistent with a cavernoma
- This corresponds to the expected distal course of the intraaxial fascicular segment of the right abducens nerve

Case: Diplopia, ? R CN III

- MRI Request: Diplopia, Suspected abnormality in right CN III. Please perform MR of the brain and orbits without and with contrast, MRA of the head
- MRA not performed due to insurance reasons
- Formal MRI read: normal
- On overread, the brain itself was normal. So were the orbits
- But…

Diplopia, ? R CN III

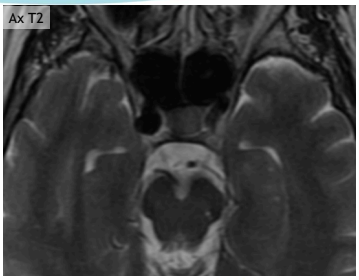

Diplopia, ? R CN III

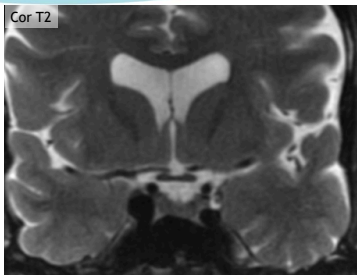

Diplopia, ? R CN III

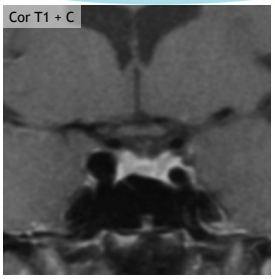

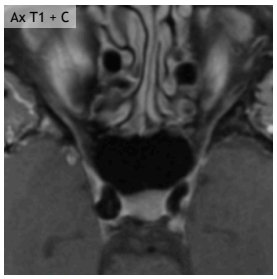

Diplopia, ? R CN III

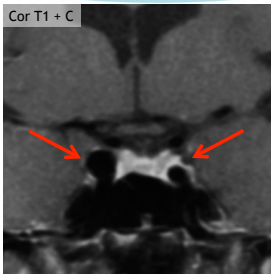

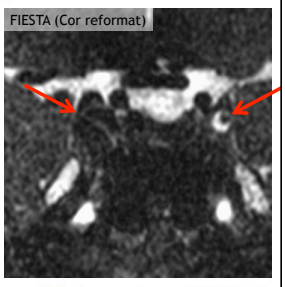

Diplopia, ? R CN III

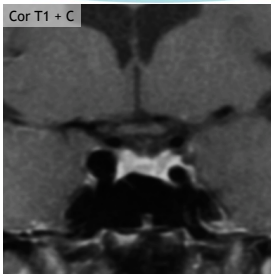

- Right cavernous carotid aneursym was confirmed
- Treated with flow diverting stent
- Improved symptoms

Case: Torsional diplopia

- Patient with torsional diplopia
  - Possible CN IV abnormality
- MRI of the brain wo/w performed, interpreted as normal
- On over-read, the brain itself was normal
- But…

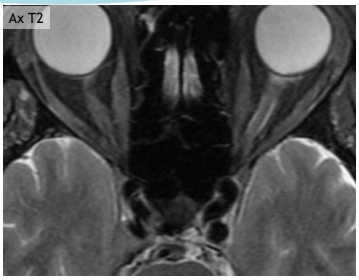

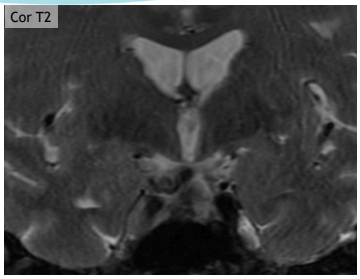

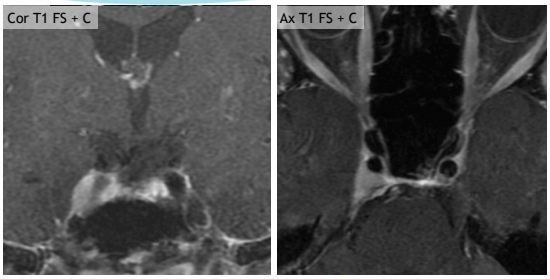

Torsional diplopia

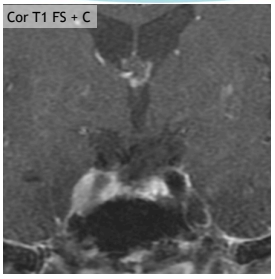

- Suspected cavernous sinus meningioma
- Treated with gamma knife
- Lesion involuted
- Diplopia/malalignment decreased
- When the diplopia remains stable, patient will likely be a candidate for strabismus surgery

Post-traumatic CN III palsy

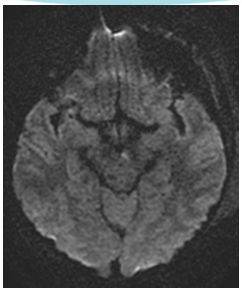

- Complete left CN III palsy after trauma
- CTA normal
- DSA normal
- MRI performed

Post-traumatic CN III palsy

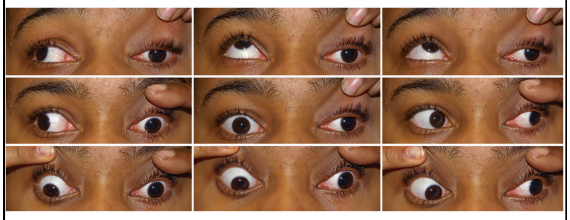

CN III avulsion

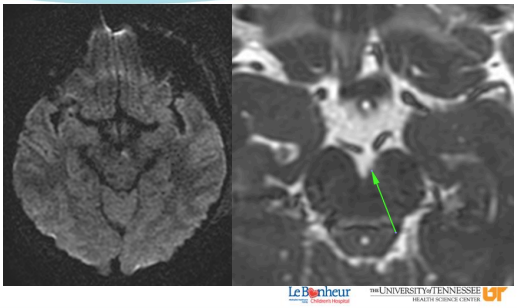

Imaging Ocular motor cranial neuropathies

- MR of the brain wo/w contrast with cranial nerve imaging
  - Cranial nerve imaging
  - Evaluate CN III, IV, and VI (the ocular motor nerves)
- Possibly also MR of the orbits wo/w contrast
- CT if post-traumatic
- Vascular imaging if CN III
- MRV if CN VI palsy and optic nerve edema

Questions to ask patients

- Duration of symptoms
  - Any instigating factors (e.g trauma)
- Side to side images, vertically deviated, etc?
- In all eye positions, or only present/exacerbated with certain gaze directions
- At all times of the day? Or only later in the day (? Myasthenia?)

Understanding their Language

- OD = right eye
- OS = left eye
- OU = both eyes
- EOM = extra-ocular muscles
- ET = esotropia (think abducens nerve)
- XT = exotropia

3D Visualization

- 3D visualization can aid in surgical planning and in education regarding the spatial relationships of cranial nerves, masses, and the skull base

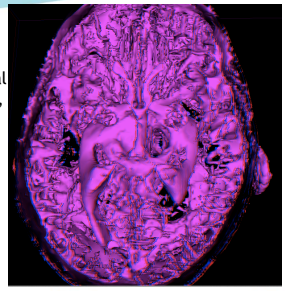

3D printing of CN

A set of high-resolution SSFP-MRI images of the brain was used to three-dimensionally reconstruct a model of the cranial nerves I-XII as they exit the brainstem.

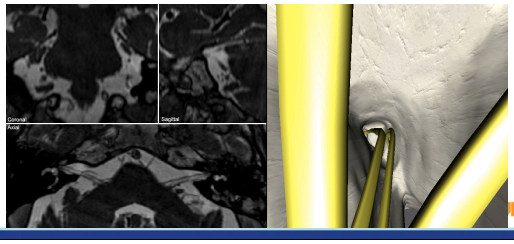

3D printing of CN

This was achieved by manually segmenting the cranial nerves slice-by-slice using Adobe Photoshop, implementing the 'Magic Wand' tool in high magnification views

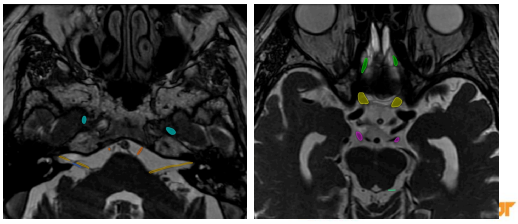

3D printing of CN

For the cranial nerves, the original grayscale images were used to manually segment the cranial nerves.

For manual segmentation of the brainstem, grayscale images were converted to black and white, since the brainstem and cerebellum were only being used as the support structure where the cranial nerves originate from and the surface details were not important in the context of this project.

Automatic segmentation was used for CT images.

3D printing of CN

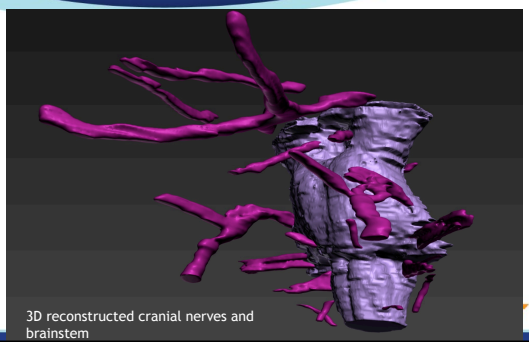

3D reconstructed cranial nerves and brainstem

3D printing of CN

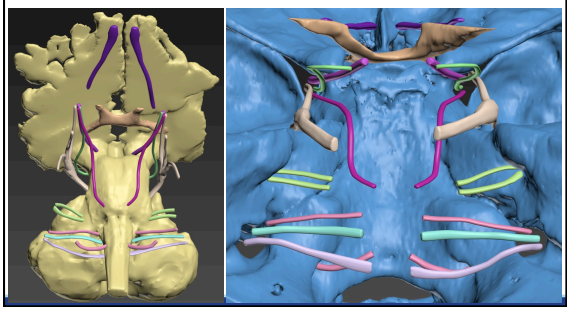

3D printing of CN

Model of the cranial nerves with brainstem and cerebellum.

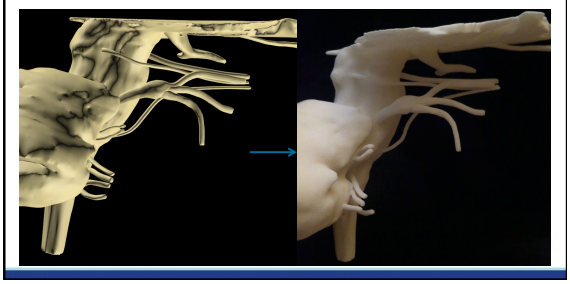

3D printing of CN

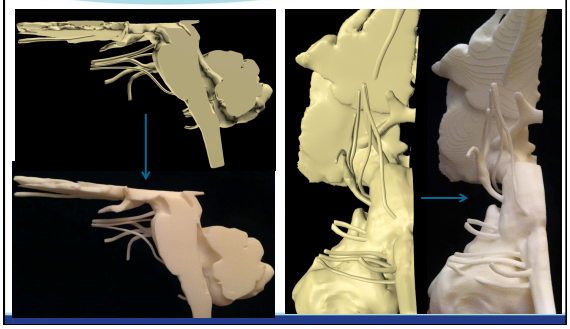

3D printing of CN

The zygoma, orbit and maxilla.



The skull base.

3D printing of CN

Cranial nerves fitted into their respective foramina and fissures.

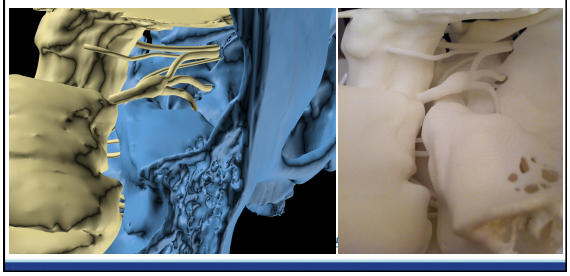

3D printing of CN

Cranial nerves and trigeminal ganglion: CNV1, CNIII, CNIV and CNVI entering superior orbital fissure, CNV2 entering foramen Rotundum and CNV3 entering foramen Ovale.

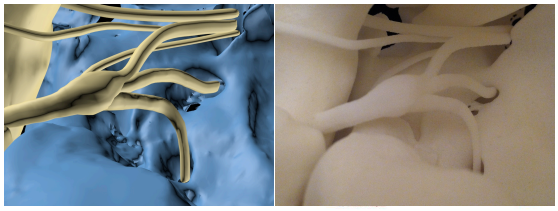

Summary

- Cranial nerves III, IV, and VI control movement of the eyes
- Diplopia is commonly associated with eye alignment abnormalities, often due to cranial nerve pathology
  - Diplopia is often the symptom through which they realize they have strabismus and/or a cranial neuropathy
- Understanding the clinical features of a patient's diplopia/ cranial neuropathy can aid in choosing the optimal study for diagnosis
- Linking the clinical to the imaging improves our ability to provide a clinically relevant consultation which hopefully helps in devising a treatment plan
- Don't forget to look at the cavernous sinus

Suggested reading

- Anatomic Considerations, Nomenclature and Cross Sectional Imaging Techniques for Visualization of the Cranial Nerves Segments by Magnetic Resonance Imaging. Blitz et al. Neuroimaging Clinics of North America 2013 (DOI: 10.1016/j.nic.2013.03.020)
- Clinical High Resolution CISS MRI Without and With Contrast For Evaluation of the Upper Cranial Nerves: Review of Segmental Anatomy and Selected Pathology of the Cisternal through Extra-Foraminal Segments . Blitz et al. Neuroimaging Clinics of North America 2013 (DOI: 10.1016/j.nic.2013.03.021)
- High-Resolution 3D Magnetic Resonance Imaging of the Sixth Cranial Nerve. Kontzialis M et al. Journal of Neuro-Ophthalmology 2015;35:412-25. DOI: 10.1097/WNO.0000000000000313)

Acknowledgements

- Thank you to the Dr. Shatzkes and the program committee of ASHNR 2018 for inviting me to speak
- Thank you to Ari M. Blitz, MD, for teaching and collaboration on high resolution cranial nerve and skull base imaging, as well as for several of the case examples
- Thank you to Lauren C. Ditta, MD, my neuro-ophthalmologist consultant
- Thank you to Ramin Javan, MD, for collaborating on 3D printing

Thank you!



Le Bonheur Children's Hospital

THE UNIVERSITY of TENNESSEE HEALTH SCIENCE CENTER