ASHNR Savannah, GA
4:50-5:05 September 27th, 2018

Segmental Approach to High Resolution MRI of the Cranial Nerves

Ari M. Blitz, MD
Associate Professor of Radiology and Neurosurgery
Director, Skull Base Imaging
Johns Hopkins University
ablitz1@jhmi.edu

JOHNS HOPKINS MEDICINE

Disclosures (Blitz)

- Honorarium, International Society for Hydrocephalus and CSF Disorders
- Medical legal consulting
- Lead radiologist, Adult Hydrocephalus Research Network (AHCRN)
- Lead radiologist, AVERT (U 01), FAIN U01DC013778
- Co-investigator, Novel Method for Volumetric Analysis of Adult Hydrocephalus R21 NS096497
- Member of the managing board, Institute for Excellence in Education, Johns Hopkins School of Medicine

- The content of this lecture does not constitute an endorsement of any product by the speaker or by Johns Hopkins Medical Institutions.

Objectives

- By the end of this talk the participant will be able to:
- 1. List the segments of the cranial nerves
- 2. Describe methods of visualization of each segment including high resolution 3D MR imaging.
- 3. Identify imaging features of primary tumors arising from the cranial nerves as well as perineural spread of disease on cross sectional imaging.

Outline

Introduction
Segmental nomenclature
General technique MRI
Cranial nerves by segment
    Imaging approach
    Anatomic images
    Pathologic cases
Summary

Cranial Nerve Anatomy

Cranial Nerve Segments An Imaging Classification

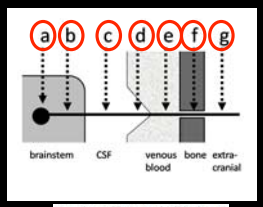

Neuroimag Clin N Am 24 (2014) 1–15

- a. nuclear
- b. parenchymal fascicular
- c. cisternal
- d. dural cave
- e. interdural
- f. foraminal
- g. extra-foraminal

(can be referred to in short hand as CN #.x where x is the segment)

Cranial Nerve Segments An Imaging Classification

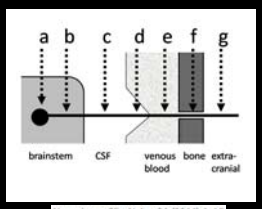

Neuroimag Clin N Am 24 (2014) 1–15

- Provides a concise, standard and specific means of communication with clinicians
- Has implications for DDX
- Alters approach to imaging

Protocol for Visualization of the CN Segments

3D Isotropic Imaging

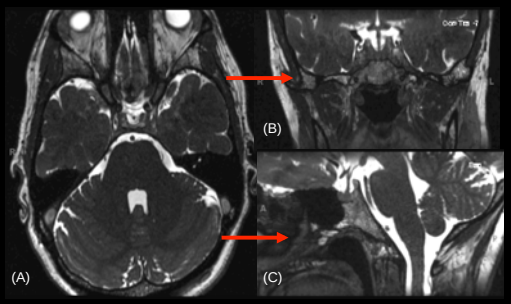

Skull Base Protocol (as hung for interpretation)

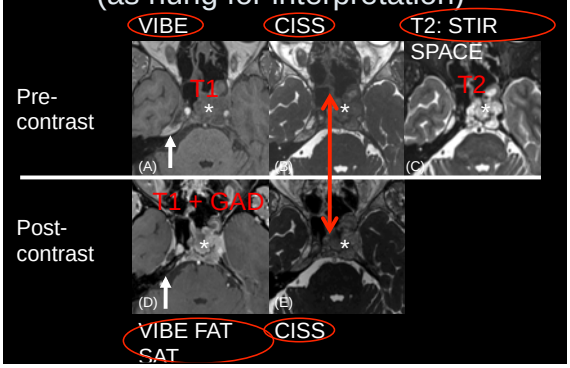

Skull Base Protocol Parameters

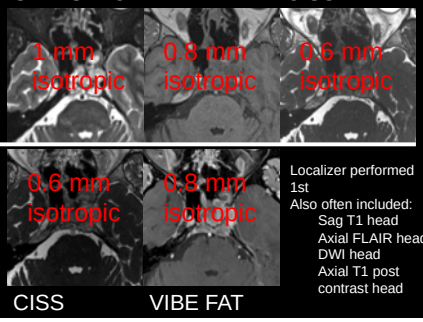

Localizer performed 1st
Also often included:
- Sag T1 head
- Axial FLAIR head
- DWI head
- Axial T1 post contrast head

Imaging Nuclear (a) and Parenchymal fascicular (b) Segments

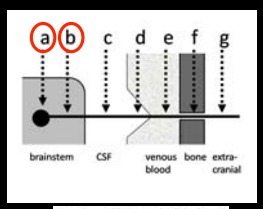

Neuroimag Clin N Am 24 (2014) 1–15

- Surrounded by brainstem parenchyma
- Not directly visualized
- The location of the CN.a and CN.b segments is deduced with respect to known anatomic landmarks
- Imaged with standard head MRI (and/or DTI)

Acute onset
right superior oblique palsy

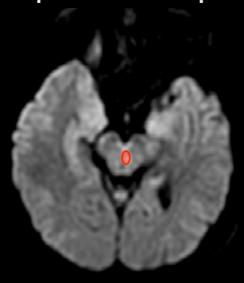

CN IV.a

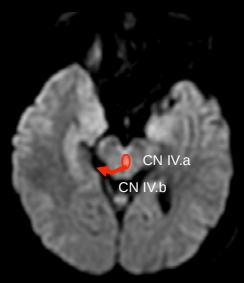

Imaging Cisternal (c) and Dural Cave (d) Segments

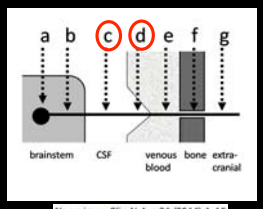

Neuroimag Clin N Am 24 (2014) 1–15

- Surrounded by cerebral spinal fluid (CSF)
- Well visualized on thin sectionT2-weighted images
- 3D SSFP or T2 SPACE

High Resolution Imaging Informs Our Knowledge in Other Cases CN III.c

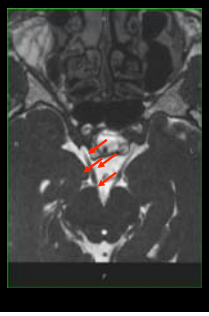

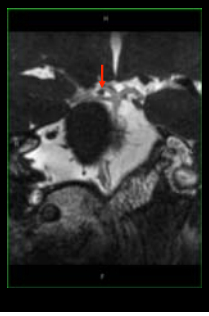

Example of Enhancement on CISS CN III.c-e Pathology

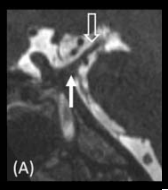

Blitz et a Neuroimag Clin N Am 24 (2014) 17–34

The Relationship of CN to Adjacent Structures on CISS CN II.c Pathology

Neuroimag Clin N Am 24 (2014) 17–34

CN III.d

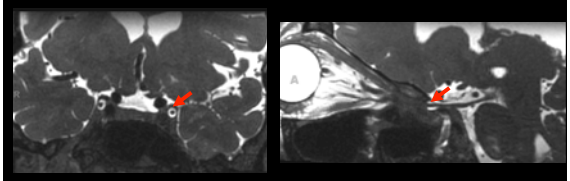

Imaging the Interdural (e) Segment

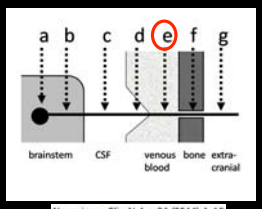

Neuroimag Clin N Am 24 (2014) 1–15

- Between inner (meningeal) and outer (periostial) layers of dura
- Surrounded by venous blood
- Not well visualized on traditional T2-weighted images
- Use contrast enhanced images
- Contrast enhanced SSFP images are

Following CN VI.c through CN VI.e

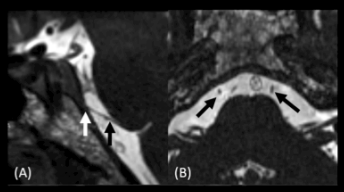

Cavernous sinus

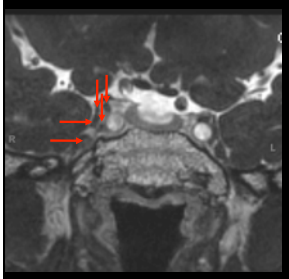

- CN III.e
- CN IV.e
- CN VI.e
- CN V.1.e
- CN V.2.e

(CISS with contrast)

CN VI.c-e Utility for Surgical Planning

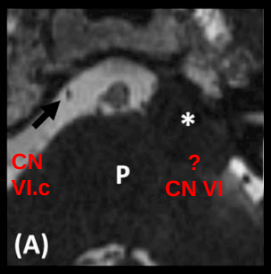

CN VI.e

Blitz et al Neuroimag Clin N Am 24 (2014) 17–34

Visualization beyond the Subarachnoid Space CN VI.e

Blitz et al Neuroimag Clin N Am 24 (2014) 17–34

Trigeminal neuralgia (Outside films submitted by referring physician)

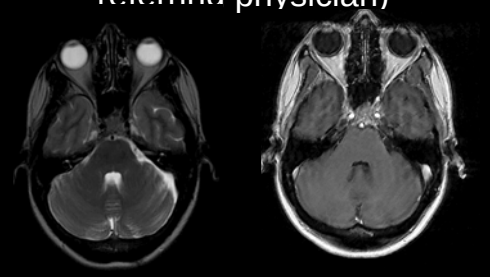

CN V.2.e Pathology Perineural spread of adenoid cystic carcinoma producing trigeminal neuralgia

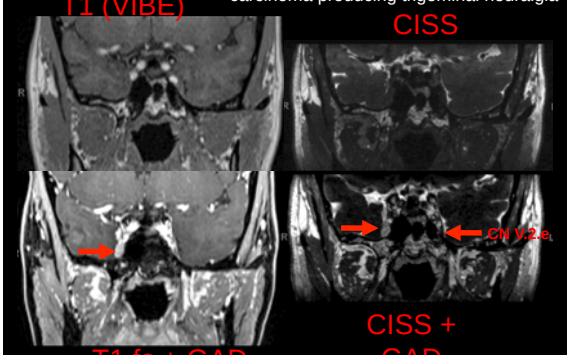

Imaging the Foraminal(f) Segment

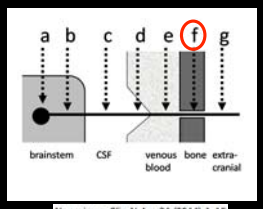

Neuroimag Clin N Am 24 (2014) 1–15

- Surrounded by venous blood and bone
- Not well visualized on traditional T2-weighted images
- Again, use contrast enhanced images
- Contrast enhanced SSFP images are ideal

CN III.f

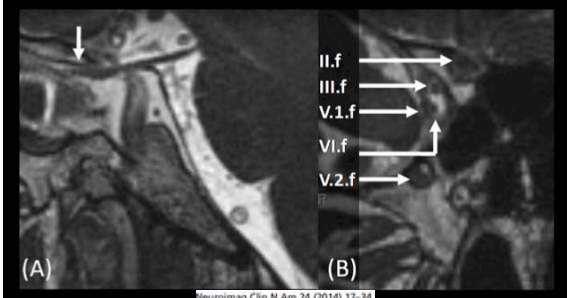

Neuroimag Clin N Am 24 (2014) 17–34

History of Optic Neuritis

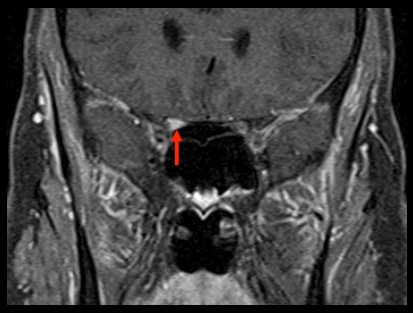

IMPRESSION: …compatible with optic neuritis…

Distinguishing Between Intrinsic and Extrinsic Abnormalities

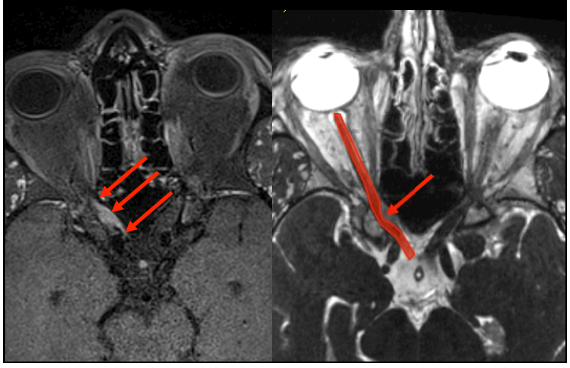

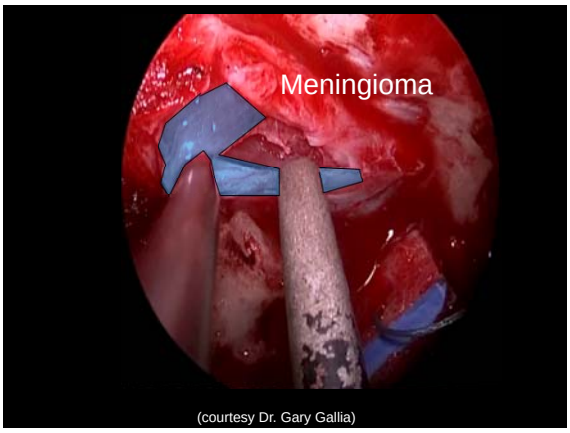

(courtesy Dr. Gary Gallia)

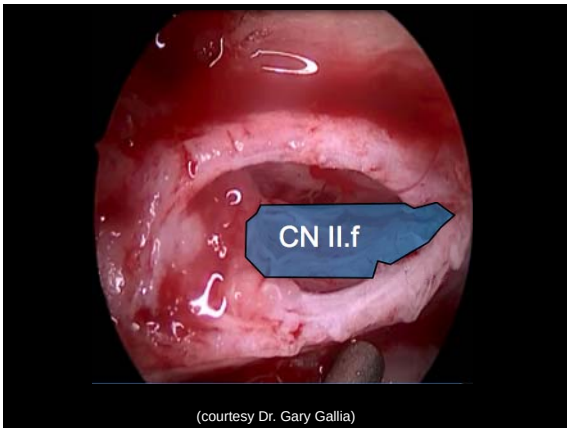

(courtesy Dr. Gary Gallia)

Imaging the Extra-foraminal(g) Segment

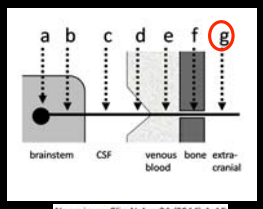

Neuroimag Clin N Am 24 (2014) 1–15

- Surrounded by muscle, fat, etc...

CN III.g (surface coil)

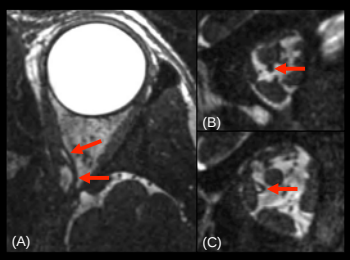

Axial (A) and coronal (B) and (C) precontrast CISS images obtained with surface coil and 0.4 mm isotropic resolution

Note individual nerve fibers of the CN III.g inferior division inserting at the junction of the posterior third and the anterior two thirds of the medial rectus muscle

Clarification of Origin of Mass CN III.g

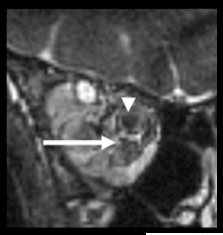

Blitz et al Neuroimag Clin N Am 24 (2014) 17–34

CN VII.g

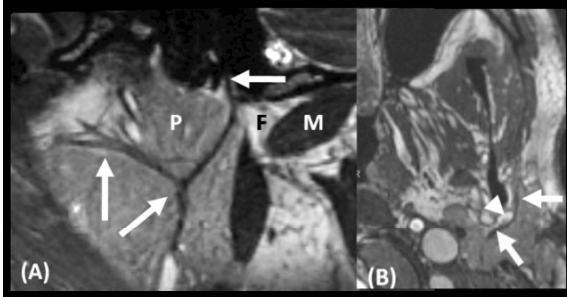

Blitz et al Neuroimag Clin N Am 24 (2014) 1–15

CN VII.g schwannoma

Pleomorphic Adenoma

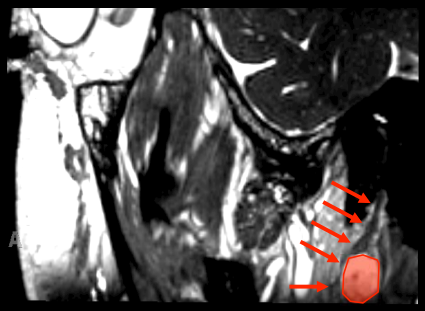

CN VII.g Perineural spread of BCC

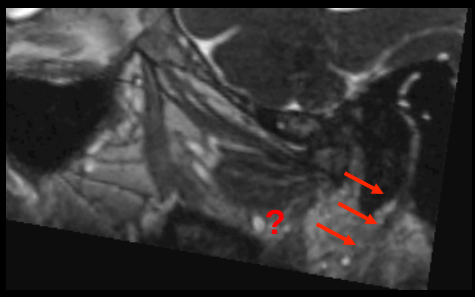

Key Points

- We divide the cranial nerves into segments based on their environment and each segment has different imaging strategies
- Imaging technique varies by segment!
- Balanced SSFP (CISS) is the heart of this approach, due to high spatial resolution and SNR, CSF flow suppression and mixed T2/T1 weighting
- Our high resolution 3D skull base protocol with contrast allows for visualization of each CN segment/ skull base layer
- The exam can be tailored by the technologist and takes ~25 minutes

- Direct visualization of CNs
- May detect abnormalities not seen on standard imaging
- Relationship of mass to CN may aid in DDX

Acknowledgements

- Neurosurgery: Gary Gallia, MD PhD
  A. Karim Ahmed
- ENT: Masaru Ishii, MD PhD
- Neuroradiology:
  - Nafi Aygun, MD
  - Marinos Kontzialis, MD
  - Leonardo Macedo, MD
  - Daniel Seebury, MD PhD
  - Benjmin Northcutt,MD
  - Nivedita Agrawal, MD
  - Jaehoon Shin, MD PhD
- Biomedical Engineering
  - William Edelstein, PhD
  - Daniel Herzka, PhD

Further reading/ citations

- Casselman, Jan W., et al. "Constructive interference in steady state-3DFT MR imaging of the inner ear and cerebellopontine angle." *American journal of neuroradiology* 14.1 (1993): 47-57.
- Badger, David, and Nafi Aygun. "Imaging of Perineural Spread in Head and Neck Cancer." *Radiologic Clinics of North America* 55.1 (2017): 139-149.
- Blitz, A. M., Macedo, L. L., Chonka, Z. D., Ilica, A. T., Choudhri, A. F., Gallia, G. L., & Aygun, N. (2014). High-resolution CISS MR imaging with and without contrast for evaluation of the upper cranial nerves: segmental anatomy and selected pathologic conditions of the cisternal through extraforaminal segments. *Neuroimaging Clinics of North America*, *24*(1), 17-34.
- Blitz, A. M., Choudhri, A. F., Chonka, Z. D., Ilica, A. T., Macedo, L. L., Chhabra, A., ... & Aygun, N. (2014). Anatomic considerations, nomenclature, and advanced cross-sectional imaging techniques for visualization of the cranial nerve segments by MR imaging. *Neuroimaging Clinics of North America*, *24*(1), 1-15.
- Blitz AM, Aygun N, Herzka DA, Ishii M, Gallia GL. High Resolution Three-Dimensional MR Imaging of the Skull Base: Compartments, Boundaries, and Critical Structures. Radiologic Clinics of North America. 2017 Jan 31;55(1):17-30.
- Kontzialis, M., Choudhri, A.F., Patel, V.R., Subramanian, P.S., Ishii, M., Gallia, G.L., Aygun, N. and Blitz, A.M., 2015. High-Resolution 3D Magnetic Resonance Imaging of the Sixth Cranial Nerve: Anatomic and Pathologic Considerations by Segment. *Journal of Neuro-Ophthalmology*, *35*(4), pp.412-425.
- Lang, J. (2012). *Clinical Anatomy of the Head: Neurocranium· Orbit· Craniocervical Regions*. Springer Science & Business Media.
- Liebig, Catherine, et al. "Perineural invasion in cancer." *Cancer* 115.15 (2009): 3379-3391.
- Seeburg DP, Northcutt B, Aygun N, Blitz AM. The Role of Imaging for Trigeminal Neuralgia: A Segmental Approach to High-Resolution MRI. Neurosurgery Clinics of North America. 2016 Jul 31;27(3):315-26.
- Wen J, Desai NS, Jeffery D, Aygun N, Blitz A. High-Resolution Isotropic Three-Dimensional MR Imaging of the Extraforaminal Segments of the Cranial Nerves. Magnetic Resonance Imaging Clinics. 2018 Feb 1;26(1):101-19.
- Yagi, A., Sato, N., Takahashi, A., Morita, H., Amanuma, M., Endo, K., & Takeuchi, K. (2010). Added value of contrast-enhanced CISS imaging in relation to conventional MR images for the evaluation of intracavernous cranial nerve lesions. *Neuroradiology*, *52*(12), 1101-1109.

Citations/ Further Reading


Anatomic Considerations, Nomenclature, and Advanced Cross-sectional Imaging Techniques for Visualization of the Cranial Nerve Segments by MR Imaging

Neuroimag Clin N Am 24 (2014) 1–15

Ari M. Blitz, MD[a,*], Asim F. Choudhri, MD[b], Zachary D. Chonka, MD[a], Ahmet T. Ilica, MD[a], Leonardo L. Macedo, MD[c], Aneesh Chhabra, MD[d], Gary L. Gallia, MD, PhD[e], Nafi Aygun, MD[a]

High-Resolution CISS MR Imaging With and Without Contrast for Evaluation of the Upper Cranial Nerves

Segmental Anatomy and Selected Pathologic Conditions of the Cisternal Through Extraforaminal Segments

Neuroimag Clin N Am 24 (2014) 17–34

Ari M. Blitz, MD[a,*], Leonardo L. Macedo, MD[b], Zachary D. Chonka, MD[a], Ahmet T. Ilica, MD[a], Asim F. Choudhri, MD[c], Gary L. Gallia, MD, PhD[d], Nafi Aygun, MD[a]

Thank you

Dr. Shatzkes!