CONDUCTIVE HEARING LOSS AND THIRD WINDOW LESIONS

Gul Moonis, M.D
Columbia University Medical Center
New York



Outline

- Physiology of hearing
- Types of hearing loss
- Lesions causing conductive hearing loss
- 3rd window lesions

Normal Air Conduction

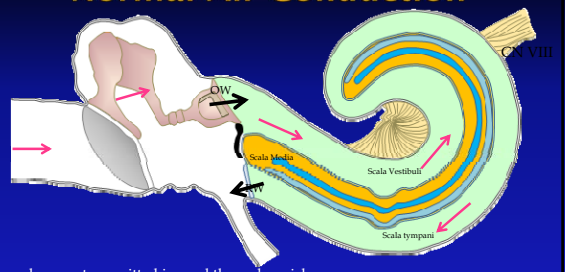

Sound waves transmitted inward through ossicles
From OW energy conducted through incompressible perilymph-equal outward motion at RW
Pressure differential between OW/RW-pressure gradient across cochlear membrane
Deflection of hair cells in scala media (endolymph)
Nervous impulses triggered in C N VIII

Normal Bone Conduction

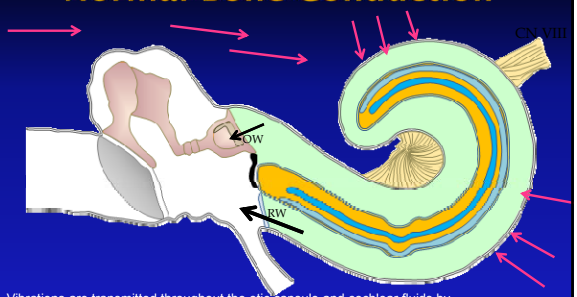

Vibrations are transmitted throughout the otic capsule and cochlear fluids by direct compression of otic capsule
Differential outward motion of the OW and RW, due to unequal impedance of these two structures.
Pressure difference across the cochlear membrane enables sound perception

Hearing Loss Types

Conductive Hearing Loss
Sound wave transmission to cochlea
CT>MRI

Sensorineural Hearing Loss
Sound wave processing in cochlea

Clinical Evaluation

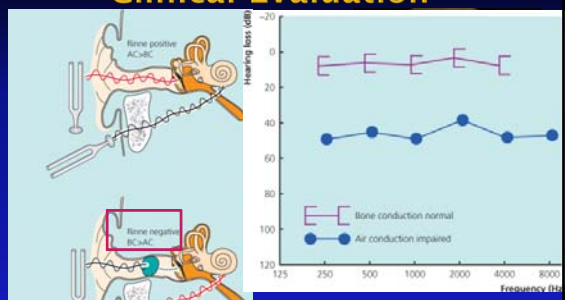

Audiogram 10 DB Air Bone Gap= CHL

Imaging of CHL

P/E Otoscopy

- Abnormal
  - EAC ME
    - Congenital
    - Trauma
    - Inflammation
    - Vascular
    - Tumor
- Normal

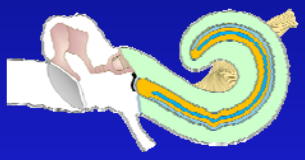

CHL

P/E Otoscopy

- Abnormal
  - EAC ME
    - Congenital
    - Tumor
    - Trauma
    - Vascular
    - Inflammation
- Normal
  - Oval window
  - Round window
  - 3rd window
  - Isolated Ossicular Lesions



3rd Window phenomenon

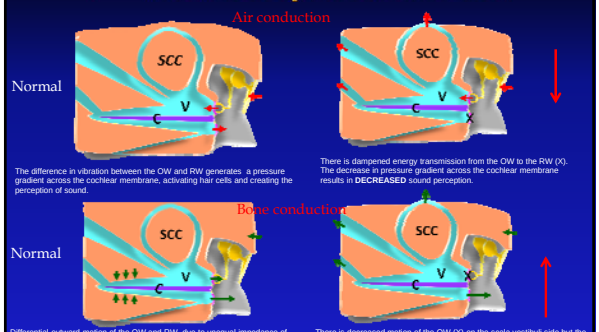

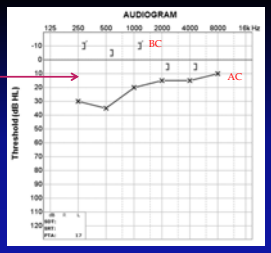

Air-bone gap at low frequencies

Audiogram of right superior semicircular canal dehiscence with increased bone conduction (*brackets*) and decreased air conduction (*crosses*). Air-bone gap exceeds 10 decibels at low sound frequencies (less than 1 KHz), for which acoustic energy is readily dissipated. At higher frequencies, there is small or no gap since proportionally less acoustic energy is shunted by the third window at these frequencies.

Superior semicircular canal dehiscense syndrome

- Tullio phenomenon
- Hennebert sign
- Autophony
- CHL
- Vertigo

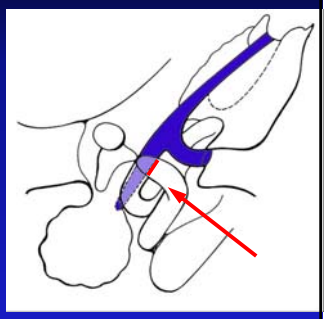

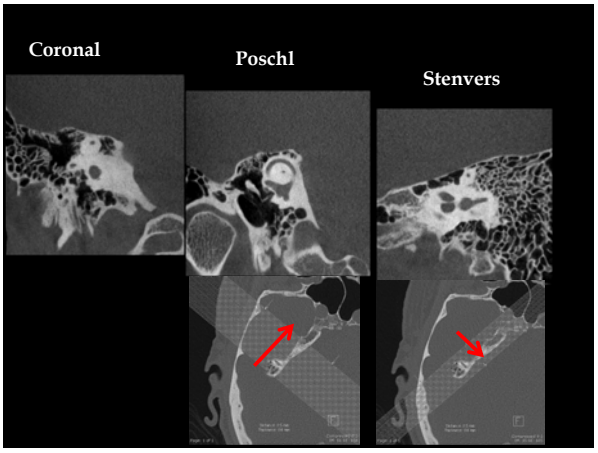

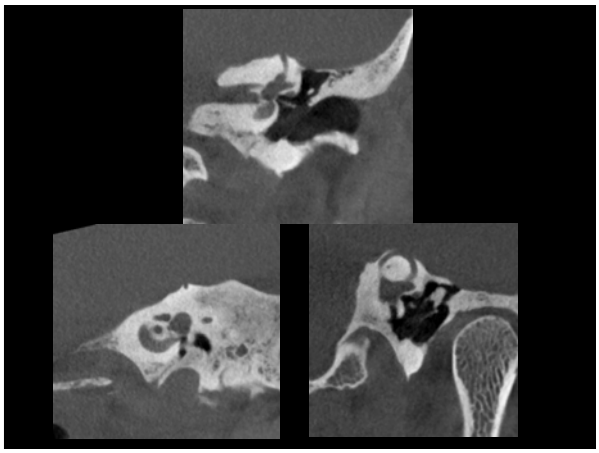

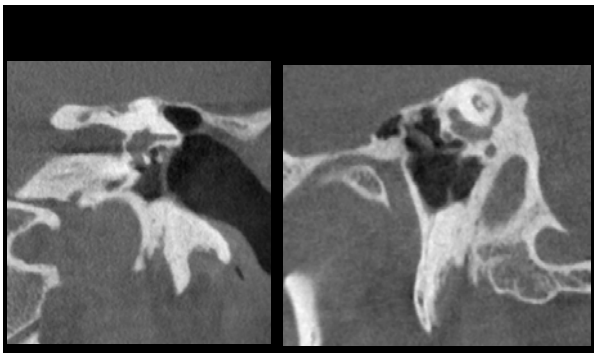

SSC obliteration

Other third window lesions

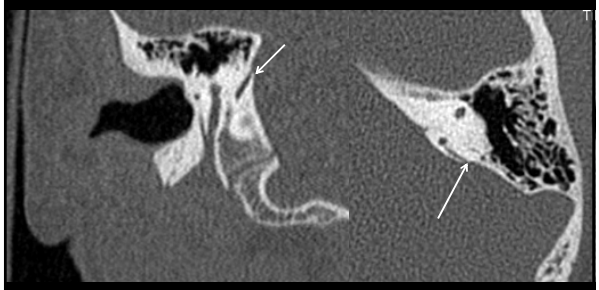

poschl Post SSCD

Other third window lesions

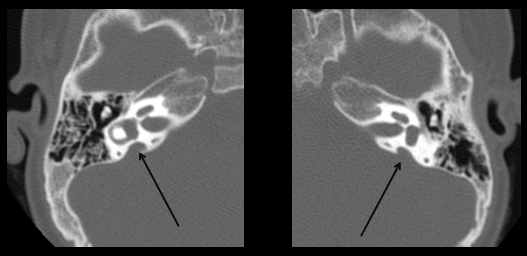

Enlarged vestibular aqueduct

CHL

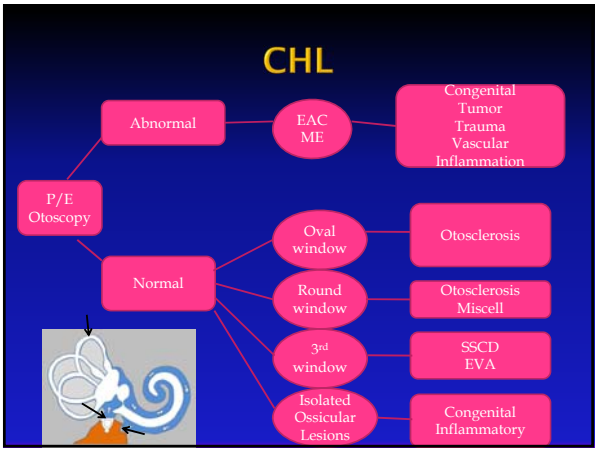

Congenital Ossicular Lesions

- Minor Malformation-Isolated Ossicular dysplasia(no EAC or TM inv)
  - Bony bar
  - Defects
  - Oval window atresia
  - Facial N dehiscense

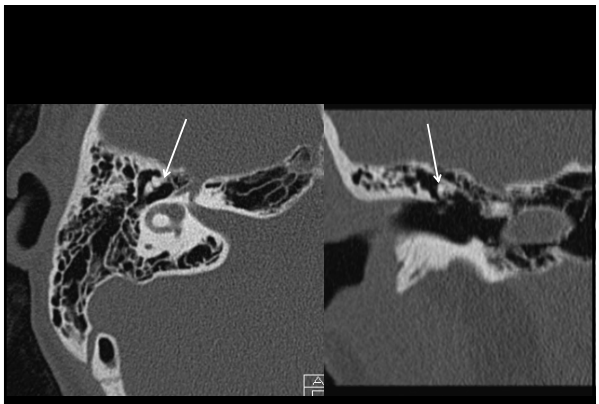

Malleus Bar

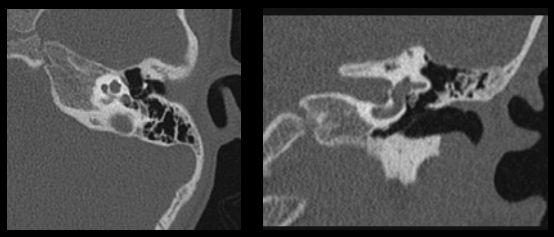

Monopod stapes, oval window stenosis, facial n dehiscence

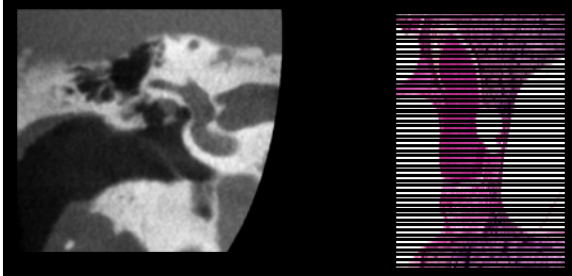

Isolated Dehiscent facial N

Isolated Inflammatory Ossicular Lesion

Hyperemic resorption of the long process of the incus

OM, isolated or after stapes prothesis placement

C/o Dr Hugh Curtin

Hyperemic Resorption of the Incus

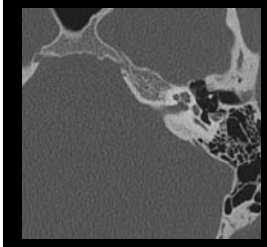

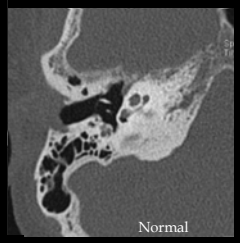

Normal

- Thank You!